HYPERACUTE INTRACEREBRAL HAEMORRHAGE DURING MRI EXAMINATION AFTER THE SURGERY OF MALIGNANT BRAIN GLIAL TUMOUR

HYPERAKÚTNE INTRACEREBRÁLNE KRVÁCANIE POČAS MR VYŠETRENIA PO OPERÁCIÍ MALÍGNEHO GLIÓMU MOZGU

case report

Robert Chrenko[1]
Kamil Koleják[2]
Jana Poláková Mištinová[3]

[1]Neurosurgical department, Landesklinikum, Wiener Neustadt, Austria

[2]Neurosurgical department, FN Nitra, Slovakia

[3]Radiology clinic, Medical Faculty, Comenius University, Bratislava, Slovakia

Accepted: 12. 2. 2017.

Corresponding adresse:
doc. MUDr. Jana Poláková Mištinová
Rádiologická klinika LF UK, SZU a UN
Mickiewiczova 13, 813 67 Bratislava, SR
e-mail: mistinova@hotmail.com

Conflict of interest: none.

Major statment
A rare case of hyperacute intracerebral bleeding captured on postoperative MRI, which allowed us to detailed observation of the series of the pathophysiological events in the first minutes of its occurrence.

Hlavné stanovisko práce
Ojedinelý prípad hyperakútneho intracerebrálneho krvácania zachyteného na MR vyšetrení, ktoré umožnilo detailne sledovať sériu patofyziologických udalostí v prvých minútach po jeho vzniku.

SUMMARY

Chrenko R, Koleják K, Poláková Mištinová J. Hyperacute intracerebral haemorrhage during MRI examination after the surgery of malignant brain glial tumour

We are describing a case of intracerebral haemorrhage into thalamus bursting into the ventricular system. Bleeding appeared during a check-up MRI examination on the first day after the surgical extirpation of a glial tumour from the temporal lobe. Initially, a hypointense deposit in T1W scan could be observed. After administration of the contrast agent the deposit gained a distinct spotty appareance. In further sequences, the progression of the bleeding and the final state stabilising after a few minutes could be observed.

Key words: hyperacute intracerebral haemorrhage, glial tumor, magnetic resonance.

SÚHRN

Chrenko R, Koleják K, Poláková Mištinová J. Hyperakútne intracerebrálne krvácanie počas MR vyšetrenia po operácií malígneho gliómu mozgu

Popisujeme prípad intracerebrálneho krvácania do talamu s prevalením do komorového systému. Krvácanie vzniklo počas kontrolného MR vyšetrenia na prvý pooperačný deň po exstirpácii gliového tumoru temporálneho laloka. Iniciálne bolo sledovateľné hypointenzívne ložisko v T1W obraze. Ložisko po podaní kontrastnej látky pri aktívnom krvácaní získalo špecifický škvrnitý obraz. V ďalších sekvenciách možno sledovať progresiu krvácania a definitívny stav, ktorý sa ustálil do niekoľkých minút.

Klúčové slová: hyperakútne intracerebrálne krvácanie, glióm mozgu, magnetická resonancia.

EPICRISIS

64-year-old patient was admitted to the neurosurgical department for the planned surgery of the solid cystic tumour in the right temporal lobe (Fig. 1). Past anamnesis included arterial hypertension with a triple combination of antihypertensive

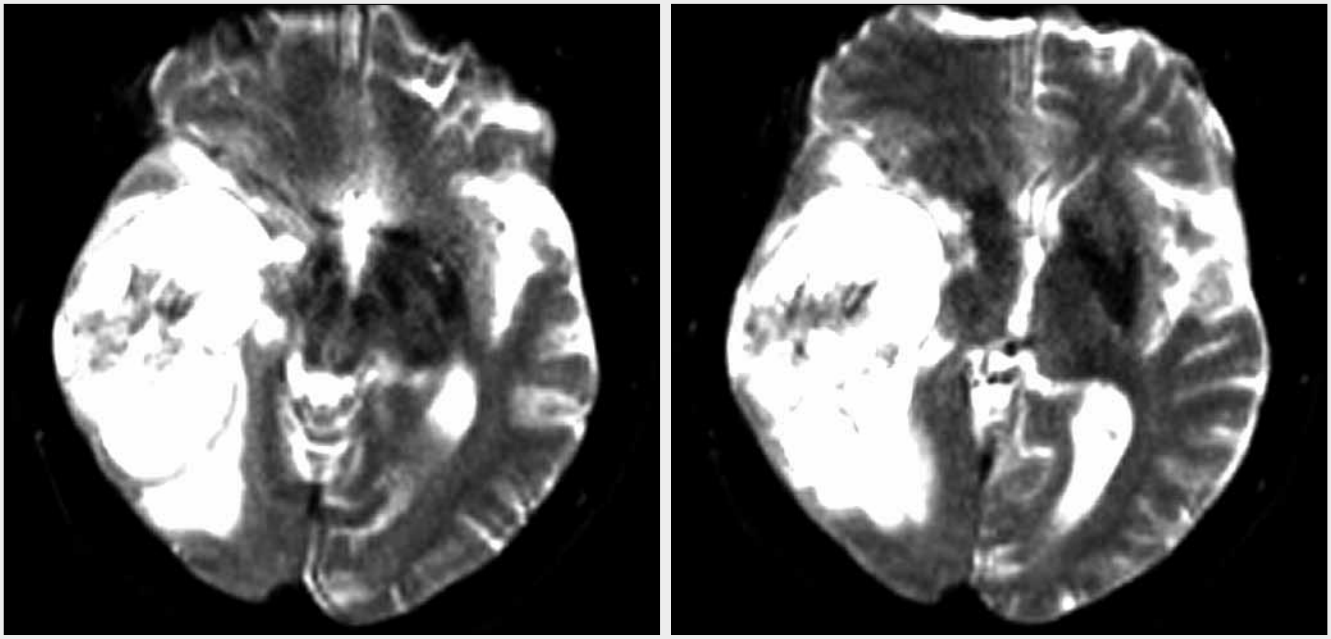

▲ Obr. 1A ▲ Obr. 1B

Fig. 1. ***A, B – MR EP2 DWI – hyperintense deposit changes in the right temporal lobe at a different clinic 17 days prior to the surgery***

medication and a post KP-resuscitation due to cardiac causes. No history of anti-coagulation or anti-aggregation treatment.

During surgery a resection of the temporal lobe and extirpation of the tumour was performed with the use of 5-ALA (5-aminolevulinic acid, Gliolan, fa. Medac GmbH, Hamburg, FRG) (Fig. 9). Due to the intra-operative fluorescence there arose a suspicion of a malignant glial tumour. The result of the histological exam showed an oligoastrocytoma WHO Gr.III (Fig. 8). Post-operative, the patient was intubated and analgosedated and moved to the ICU. Surgery and the initial post-operative period was without any extraordinary events.

24-hours after the surgery, a planned post-operative MRI exam of the brain took place. During the MRI exam the patient developed an intracerebral haemorrhage bursting into the ventricular system and the resection cavity (Fig. 2–7). The patient was monitored during the entire examination and his vital functions were stable. After his return to the ICU an anisocoria with the dilated left pupil without puppilary light reflex was observed and within minutes a bilateral mydriasis without brain stem reflexes.

Neurosurgeon inserted an external drain into the right lateral ventricle with the continual monitoring of ICP (Neurovent, fa. Raumedic, Rehau GmbH, Guntramsdorf, Austria). Bloody fluid was drained with the initial pressures of 25 mmHg. ICP normalised after the procedure and left pupil contracted temporarily, still without pupilary light reflex and stem reflexes. On the third post-surgical day exitus letalis was proclaimed with the symptoms of cardiac failure. Pathological and anatomical autopsy was performed.

DISCUSSION

Bleeding appears in 2.2% of patients after the intracerebral supratentorial tumour operations. The overall mortality from neurosurgical post-surgery bleeding is 32% (10). Bleeding most commonly takes place in the intraparenchymal, ususally in the location of the surgery (33/40), even though, in some patients (7/40) the bleeding occurs in a location more distant from the surgery. Bleeding usually happens within the first few hours and days after the surgery (within 12 hours from surgery in 35%). Potential risk factors seem to be the haemocoagulation disorder and hypertension. The most common clinical symptom is the loss of consciousness that was present in all the patients (11).

Acute haematoma (0–12 hours), in the period of oxyhaemoglobin, can be seen in T1W image either isointensely or hypointensely, in T2W image hypointensely. Traces of deoxyhaemoglobin can, however, be captured in the first minutes after the bleeding and so it is possible to observe a gradually appearing border of the lower signal intensity at the edge of the deposits in the T2W in the hyperacute phase. This enables the substitution of the CT exam by introducing the gradient sequences T2W (1–4) into the examination's protocol for the diagnostics of the acute ischemic stroke.

It is rare to capture the hyperacute bleeding during an MRI examination. An asymmetrical expansion of the hyperacute hemorrhage in a patient suffering from a cerebral amyloid angiopathy (CAA) has been described with the conclusion that the expansion of the haematoma can occur as a result of local cascade of the secondary vessel ruptures as opposed to the bleeding from one ruptured vessel (12). Cases of intraventricular and subarachnoid bleeding during MRI examination with to the extravasation of the contrast fluid were described (5–8).

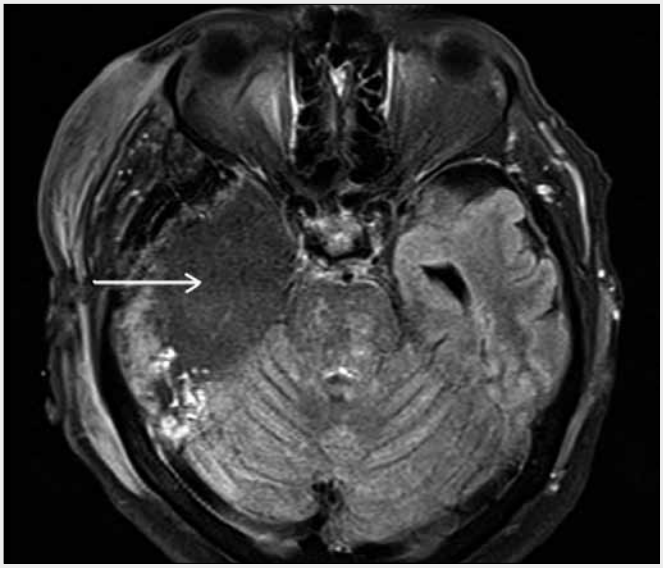

▲ Obr. 2A

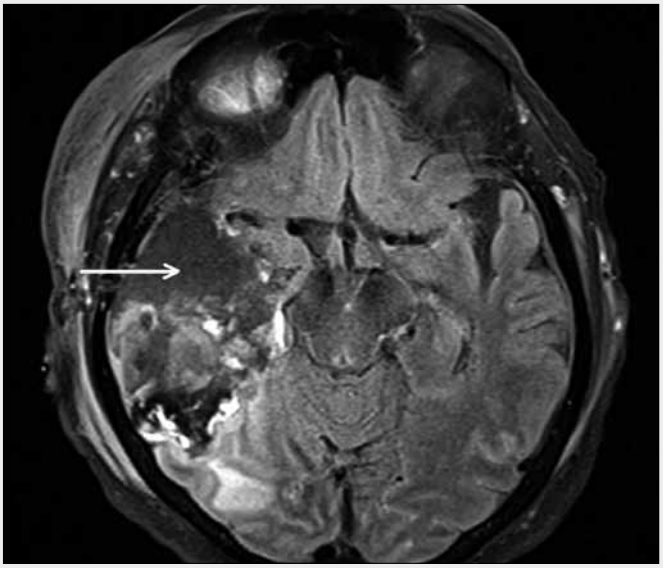

▲ Obr. 2B

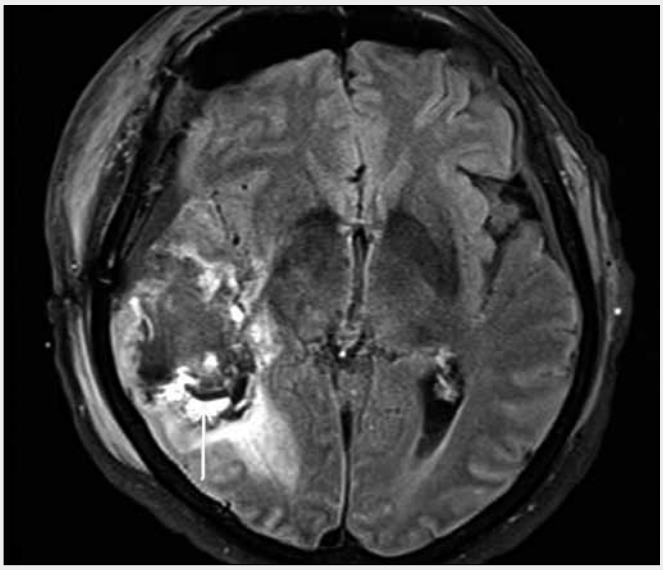

▲ Obr. 2C

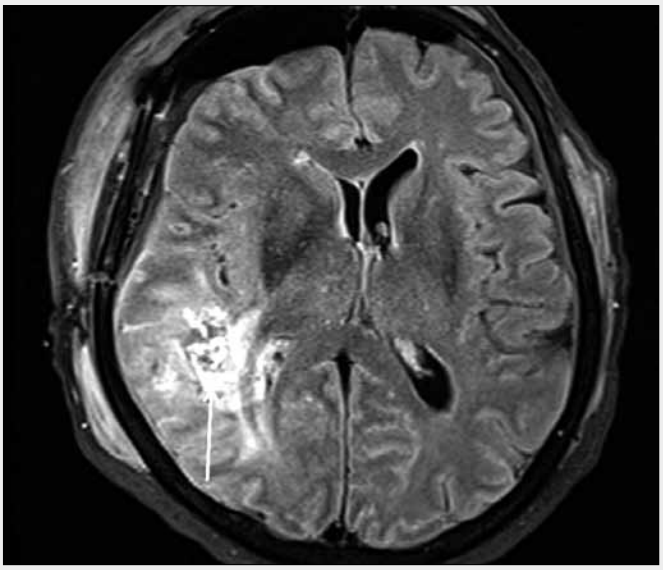

▲ Obr. 2D

Fig. 2. ***MR T2W TIRM, 11:09 am, perceptible resection cavity after the extirpation of the tumour with blood in its dorsal part (green arrows)***

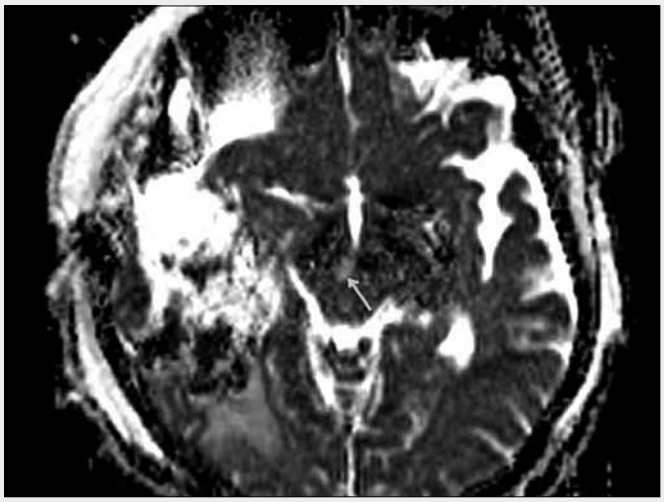

▲ Obr. 3A

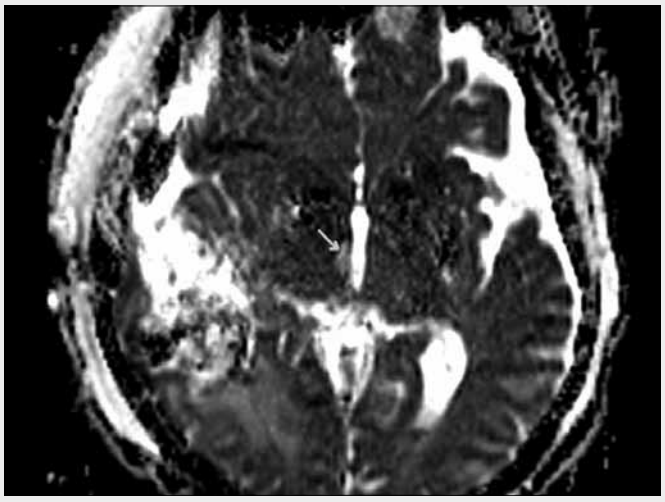

▲ Obr. 3B

Fig. 3. ***A, B – MR EP2 DWI, 11:16 am, hyperintense deposit can be observed in the thalamus area and the upper part of the mesencephalon (turquoise arrows). Its localisation corresponds with the epicentre of the haematoma (Fig. 4)***

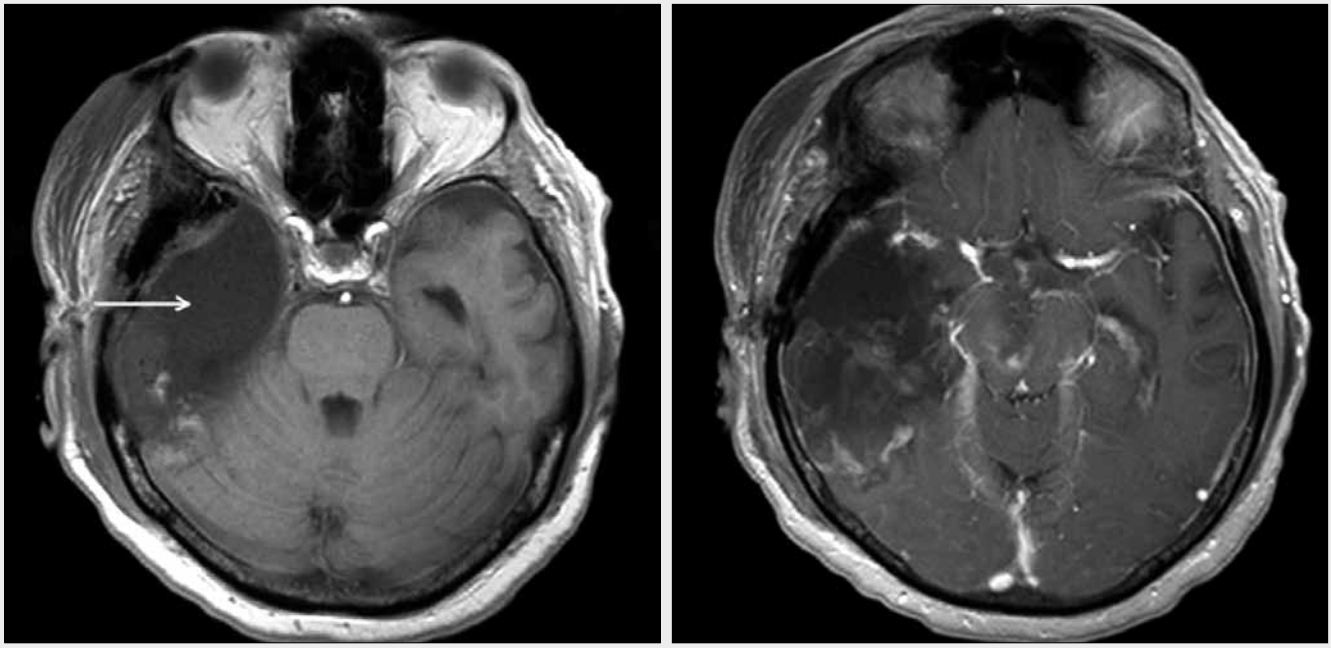

▲ Obr. 4A ▲ Obr. 4B

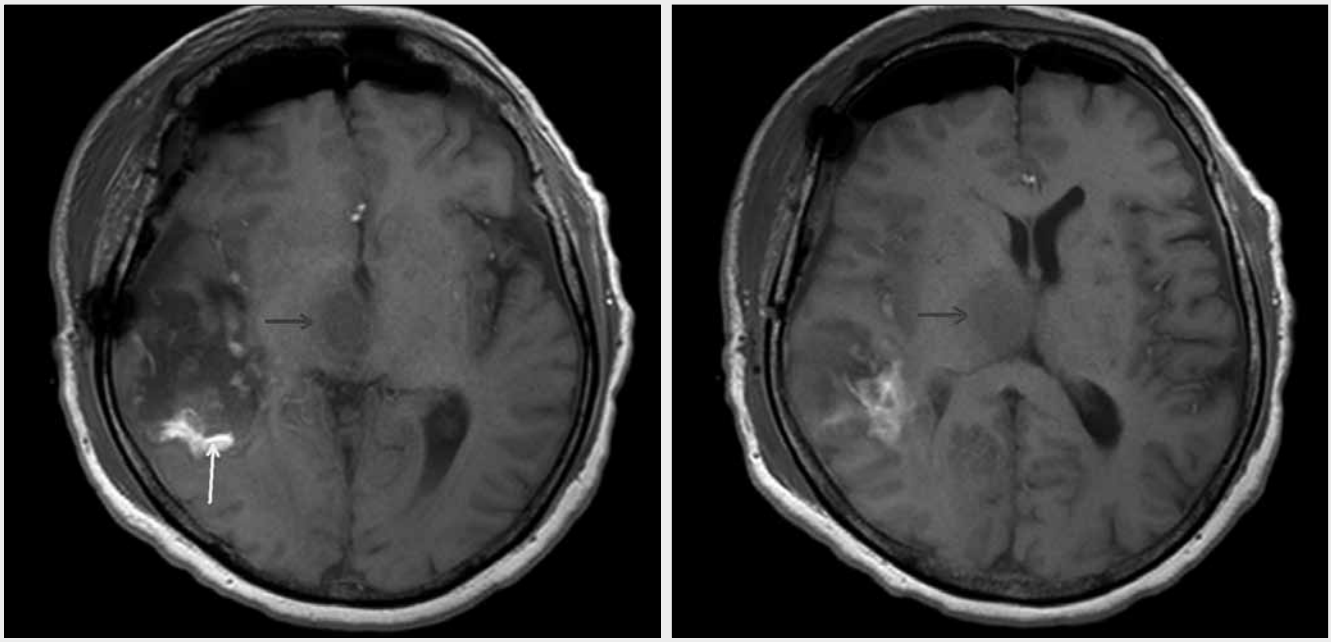

▲ Obr. 4C ▲ Obr. 4D

Fig. 4. ***MR T1W GE, 11:16 am, with no sign of contrast enhancement (yellow arrows),***
Pictures 4C and 4D – imaging of the circular slightly hypointense expansive deposit with the characteristics of a haematoma in the medial part of the right thalamus and the upper mesencephalon (purple arrows)

Table 1. ***Time frame of the expansion of the bleeding***

Time (min:sec)	Imaging modality	Volume total (ml)	Volume % expansion
00:00	MR EP2 DWI	0.55	N/A
00:11	MR T1W GE	3.33	605%
03:18	MR T1W GE Omniscan	30.4	912%
06:04	MR T1W MPRAGE	153	503%

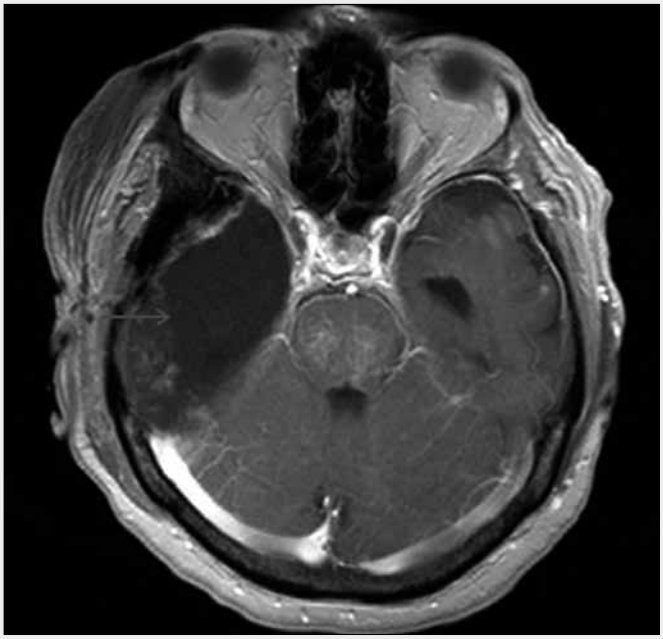

▲ Obr. 5A

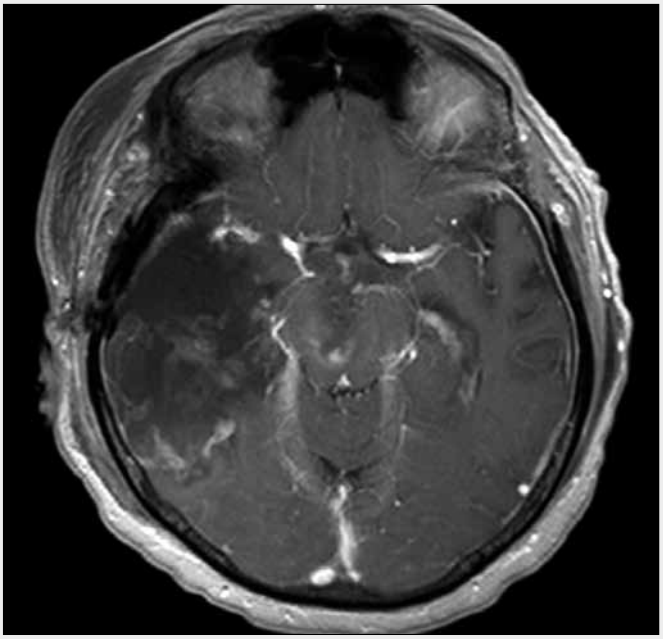

▲ Obr. 5B

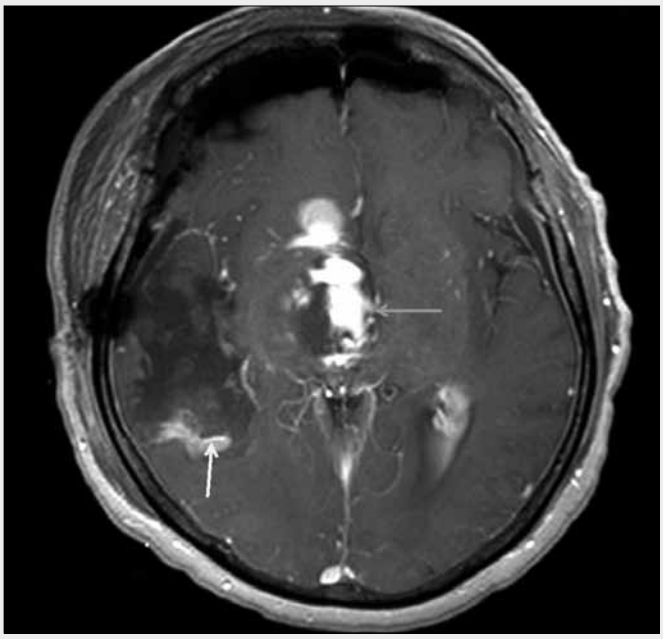

▲ Obr. 5C

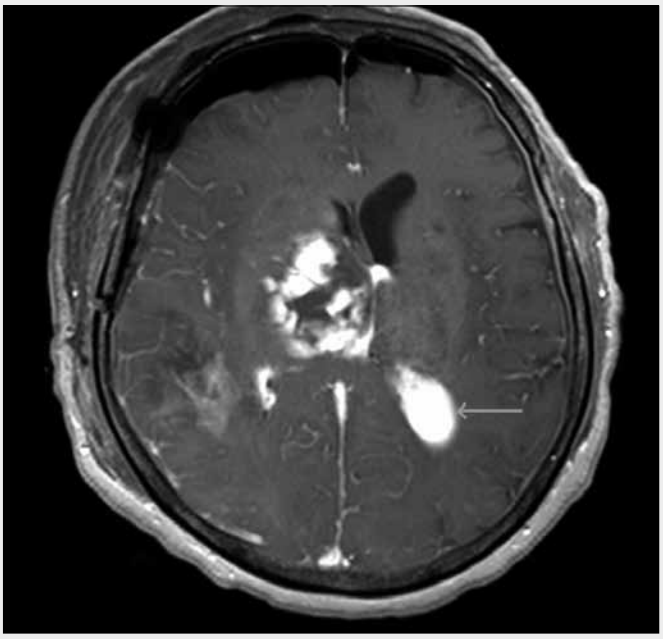

▲ Obr. 5D

Fig. 5. ***MR T1W GE + Omniscan 12ml (Gadodiamid, fa. GE Heathcare Handels GmbH, Austria) 11:19 am.*** *A, B – with no sign of contrast enhacement (yellow arrows); C, D – post-contrast imaging of the macular hyperintense deposits with the characteristic of a haematoma with the mixture of the contrast fluid and the bursting into the ventricular system (orange arrows)*

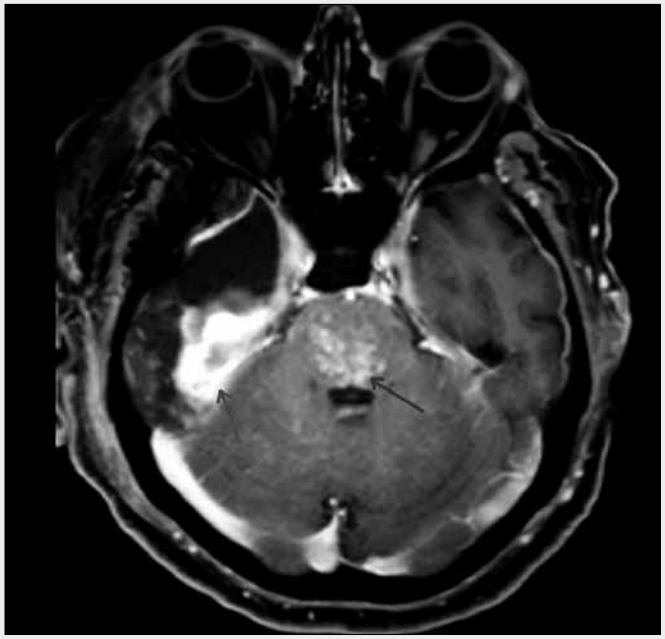

▲ Obr. 6A

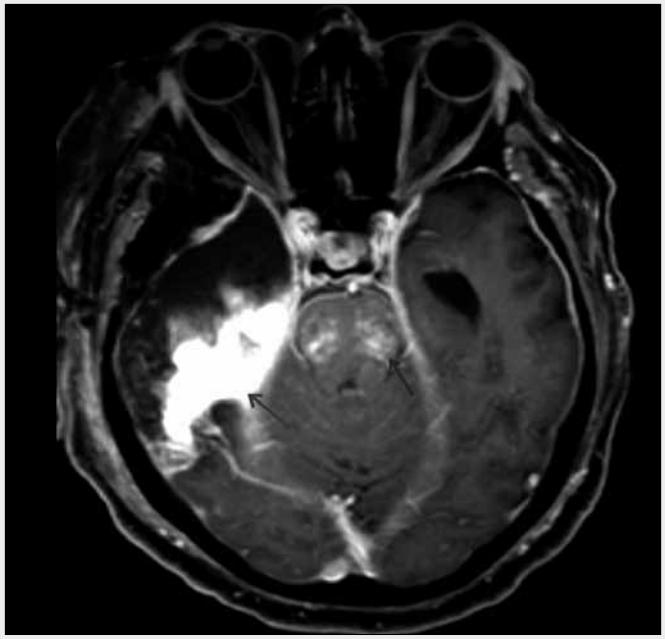

▲ Obr. 6B

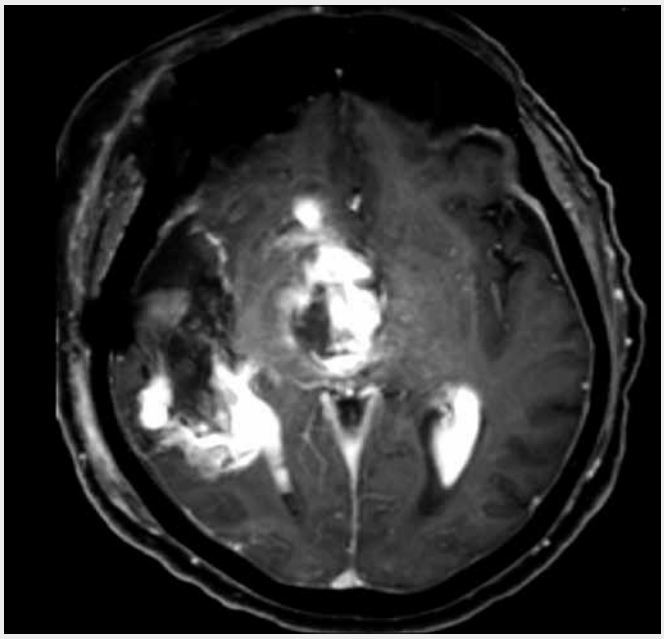

▲ Obr. 6C

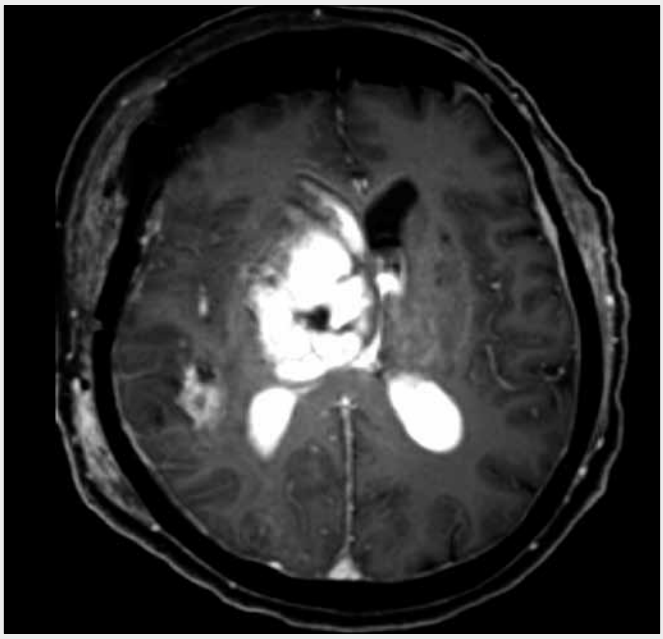

▲ Obr. 6D

Fig. 6. ***MR T1W MPRAGE, 11:22 am, bursting of the haemorrhage into the back part of the resection cavity (brown arrows) and the increase of the haematoma in the thalamus part and the ventricular system (C, D). Diffusive contrast enhancement in the area of the pons with the characteristics of the venostasis (blue arrows) (A, B).***

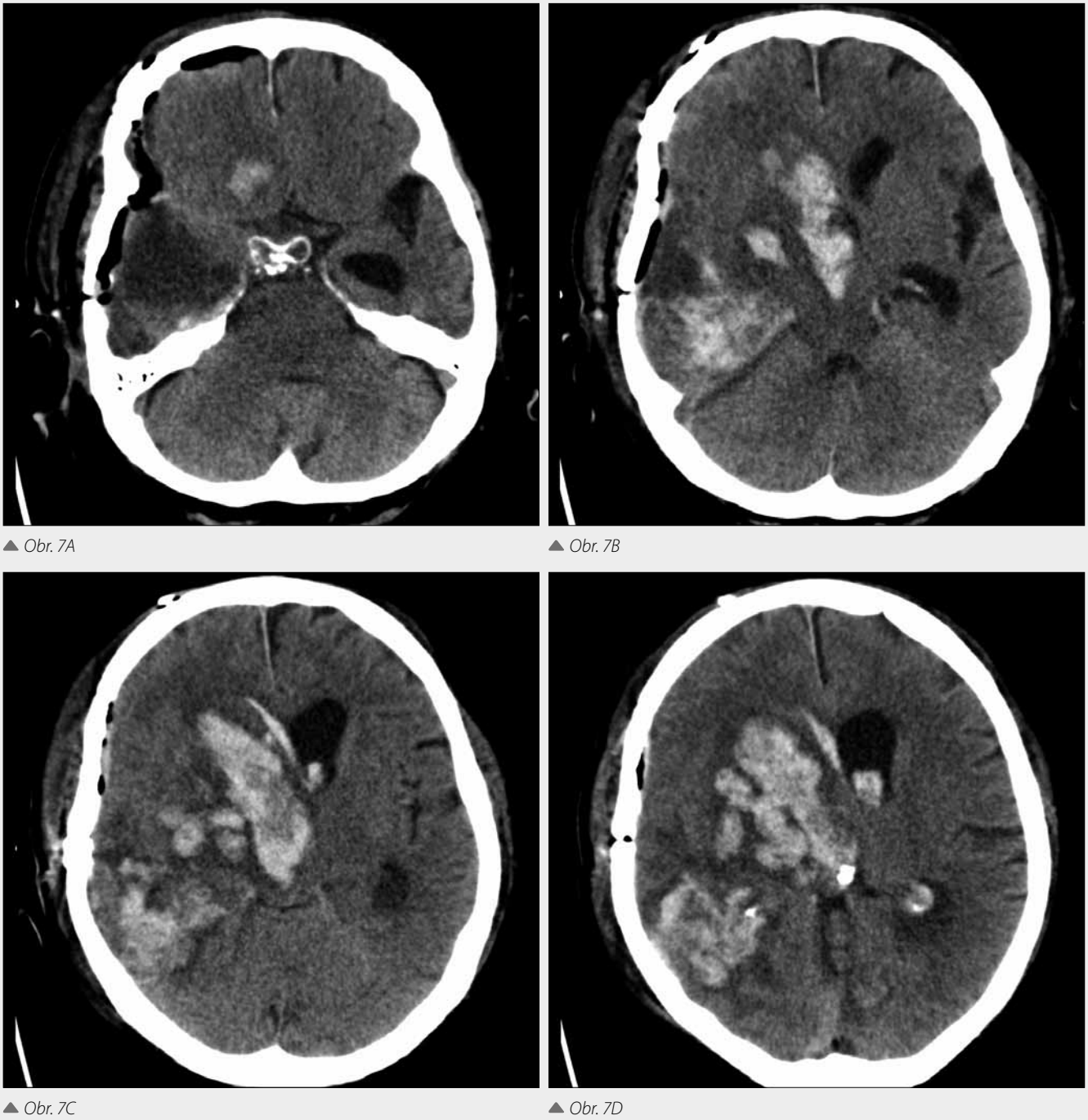

▲ Obr. 7A ▲ Obr. 7B

▲ Obr. 7C ▲ Obr. 7D

Fig. 7. ***Native CT exam, 1:35 pm, imaging of the haematoma during the CT exam. Enlargement of the ventricular system with the characteristics of the obstructive hydrocephalus can be observed.***

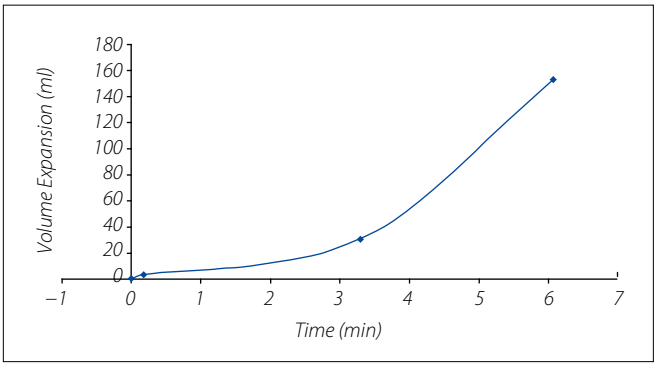

Graph 1. ***Time curve of the expansion of the bleeding has a logarithmic shape.*** *Initially, the bleeding had a symmetrical shape (Fig. 4). Its epicentre was projected into the medial area of the right thalamus and mesencephalon. Following development showed an asymmetrical expansion and the bursting of the haematoma into the vetricular system and the resection cavity. The growth of the haematoma volume accelerated (Fig. 5). Haematoma subsequently reached its final volume and shape (Fig. 6).*

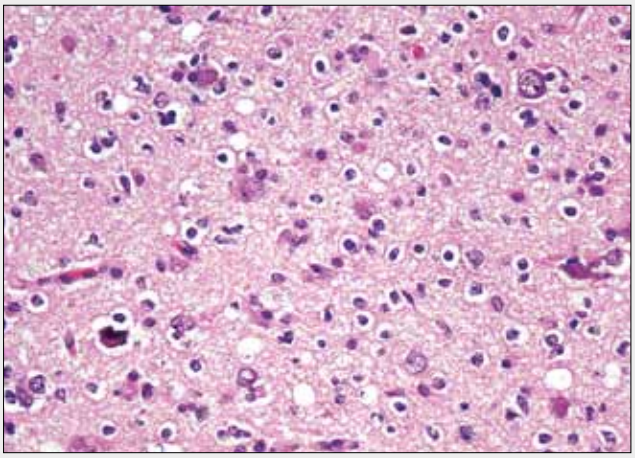

▲ Obr. 8

Fig. 8. ***Histological report. Histopathological show a medium hypercellular glial tumour consisting of astrocyte and oligodendroglioma components (HE significant enlargement). The astrocyte component is mainly protoplasmic with a small component of fibrillary astrocytess. Both components exhibit a medium nuclear pleomorphism. Medium amount of small gemystocytes and glial fibrillary oligodendrocytes is identified. Oligodendroglioma component manifested a medium mitotic activity, deposits of the microvascular proliferation with endothelial hyperplasia and small necrotic focus. Conclusion: Oligoastrocytoma WHO Gr. III.***

In the presented case, the bleeding coincided with the brain tumour surgery. During the evaluation of the post MRI, shortly before the occurrence of the bleeding, a small hyperintense deposit in the area of the right thalamus and mesencephalon appeared in the MR DWI sequence. This deposit was projected onto the epicentre of the bleeding and it was not perceptible at the examination 17 days before the surgery. In its initial stage, the hemorrhage had a symmetrical shape. In the following course, however, an asymmetrical intracerebral expansion appeared, similar as the case of the patient with CAA (12), followed by a bursting of the haematoma into the ventricular system and the resection cavity. Acceleration of the volume expansion of the haematoma took place in this stage. Diffuse postcontrast enhancement, probably, as a result of the venostasis caused by the pressure effect of the haematoma onto the venous drainage system. A similar occurrence was described by MRI in a case of carotid cavernous fistula (9).

We presume that the presented case has characteristics of a thalamic hemorrhage coincidentally occurring at the same time as the brain tumour surgery. The role of the surgery itself in relation to the hemorrhage is unclear.

CONCLUSION

We present the course of a hyperacute intracerebral hemorrhage during an MRI examination. The imaging of the expansion of the hemorrhage enables a detailed observation of the series of the pathophysiological events in the first minutes of its occurrence.

Abbreviations used

5-ALA	5-aminolevulinic acid
CAA	cerebral amyloid angiopathy
CP	cardiopulmonary
EP DWI	echo planar diffusion weighted imaging
FRG	Federal Republic of Germany
GE	gradient echo
HE	hematoxylin/eosin
ICP	intracranial pressure
MPRAGE	magnetisation prepared rapid acquired gradient echoes
MRT	magnetic resonance tomography
T1W	T1 weighted image
T2W	T2 weighted image
TIRM	turbo inversion recovery magnitude
WHO	World Health Organisation

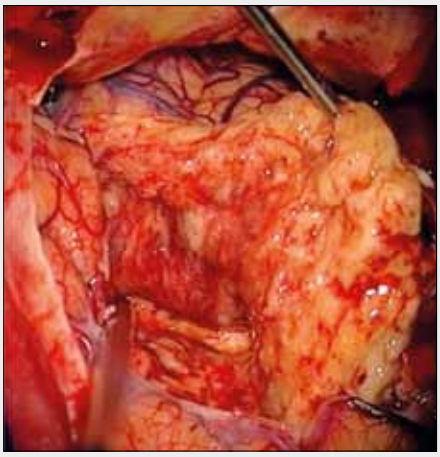

▲ Obr. 9A

▲ Obr. 9B

Fig. 9. ***Tumorous infiltration of the temporal cortex can be seen in the microscopic image using white light (A); using a 440 nm filter shows dark red tumorous tissue that can be differentiated from the cortex (B)***

REFERENCES

1. **Bradley WR Jr.** MR appearance of hemorrhage in the brain. Radiology 1993; 189(1): 15–26. ISSN 0033-8419.
2. **Linfante I, Llinas RH, Caplan LR, Warach S.** MRI features of intracerebral hemorrhage within 2 hours from symptom onset. Stroke 1999; 30(11): 2263–2267. ISSN 0039-2499.
3. **Atlas SW, Thulborn KR.** MR detection of hyperacute parenchymal hemorrhage of brain. AJNR Am J Neuroradiol 1998; 19(8): 1471–1507. ISSN 0195-6108.
4. **Seidl Z, Vaněčková M.** Magnetická rezonance hlavy, mozku a páteře. Praha: Grada Publishing 2007; 117–120. ISBN 978-80-247-1106-5.
5. **Allan RS, Parker G, McGee-Collet M.** Rupture of cerebral aneurysm during MR imaging: Leakage of gadolinium into the subarachnoid space. AJNR Am J Neuroradiol 2005; 26(1): 200–201. ISSN 0195-6108.
6. **Castillo M, Strobl P.** Intraventricular hemorrhage during MR Imaging. AJR Am J Roentgenol 1998; 171(3): 896–897. ISSN 0361-803X.
7. **Gilleland GT, el Gammal T, Fischer WS.** Hyperacute intraventricular hemorrhage revealed by gadolinium-enhanced MR imaging. AJR Am J Roentgenol 1998; 170(3): 787–789. ISSN 0361-803X.
8. **Rumboldt Z, Kalousek M, Castillo M.** Hyperacute subarachnoid hemorrhage on T2-weighted MR images. AJNR Am J Neuroradiol 2003; 24(3): 472–475. ISSN 0195-6108.
9. **Murata H, Kubota T, Murai M, Kanno H, Fujii S, Yamamoto I.** Brainstem congestion caused by direct carotid-cavernous fistula. Neurol Med Chir (Tokyo) 2003; 43(5): 255–258. ISSN 0470-8105.
10. **Palmer JD.** Postoperative hematoma: a 5-year survey and identification of avoidable risk factors. Neurosurgery 1994; 35(6): 1061–1104; discussion 1064–1065. ISSN 0148-396X.
11. **Kalfas IH, Little JR.** Postoperative hemorrhage: a survey of 4992 intracranial procedures. Neurosurgery 1988; 23(3): 343–347. ISSN 0148-396X.
12. **Edlow BL, Bove RM, Viswanathana A, Greenberg SM, Silverman SB.** The pattern and pace of hyperacute hemorrhage expansion. Neurocrit Care 2012; 17(2): 250–254. ISSN 1541-6933.