original article

Chest CT: A Valuable Tool in Discrimination of COVID-19 Pneumonia, Community Acquired Pneumonia and the Other Pathologies in Slow Epidemic Phase

CT hrudníku jako nástroj k odlišení COVID-19 pnemonie, komunitní pneumonie a ostatních patologických stavů v době pomalu probíhající epidemie

Jiří Ferda[1], Martin Vítovec[1], Jan Baxa[1], Dalibor Sedláček[2], David Havel[3], Ondřej Topolčan[4], Radek Kučera[4], Jan Beneš[5], Martin Matějovič[6], Hynek Mírka[1]

[1]Department of the Imaging, University Hospital Pilsen, Czech Republic
[2]Department of Infectious Diseases, University Hospital Pilsen, Czech Republic
[3]Department of Respiratory Diseases, University Hospital Pilsen, Czech Republic
[4]Division of the Immunodiagnostics, University Hospital Pilsen, Czech Republic
[5]Department of the Anesthesiology, Resuscitation and Intensive Care, University Hospital Pilsen, Czech Republic
[6]1st Department of Internal Medicine, University Hospital Pilsen, Czech Republic

Accepted: 15. 9. 2020

Correspondence address:
prof. MUDr. Jiří Ferda, Ph.D.
Department of the Imaging
University Hospital Pilsen
Edvarda Beneše 13, 305 99 Pilsen, Czech Republic
e-mail: ferda@fnplzen.cz

Conflict of interest: none.

Supported by the projects Conceptual development of the Research institution 00669806 – FN Plzeň and Charles University Project Progress q39.

Major statement
Computed tomography is a valuable tool in the discrimination of hte COVID-19 pneumonia, community acquired pneumonia and other pathologies, when the epidemic is slowly developing.

Hlavní stanovisko práce
V době pomaleji se rozvíjející epidemie je výpočetní tomografie cenným nástrojem k odlišení COVID-19 pneumonie, komunitní pneumonie a dalších plicních patologických stavů.

SUMMARY

Ferda J, Vítovec M, Baxa J, Sedláček D, Havel D, Topolčan O, Kučera R, Beneš J, Matějovič M, Mírka H. Chest CT: A Valuable Tool in Discrimination of COVID-19 Pneumonia, Community Acquired Pneumonia and the Other Pathologies in Slow Epidemic Phase

Aim: SARS-CoV-2 infection manifests like COVID-19 pneumonia, computed tomography (CT) has been reported as its valuable imaging. Frequent arguments against are discussed: the problem of the possible further spread of the infection to medical staff and/or other patients, and also insufficient SARS-CoV-2 detectability based solely on CT. The aim of the study was to examine the usefulness of CT for personalized, precision and predictive diagnostics of COVID-19-suspected.

Method: Chest CT was performed due to suspected COVID-19 pneumonia in 310 patients during slow epidemic in Czech Republic, during March and April 2020. All patients underwent sampling for RT-PCR to confirm SARS-CoV-2

SOUHRN

Ferda J, Vítovec M, Baxa J, Sedláček D, Havel D, Topolčan O, Kučera R, Beneš J, Matějovič M, Mírka H. CT hrudníku jako nástroj k odlišení COVID-19 pnemonie, komunitní pneumonie a ostatních patologických stavů v době pomalu probíhající epidemie

Cíl: SARS-CoV-2 infekce se manifestuje jako COVID-19 pneumonie, použití výpočetní tomografie (CT) je diskutováno zejména kvůli argumentaci proti – možnost šíření infekce na zdravotnický personál nebo na jiné nemocné – a insuficience detekce SARS-CoV-2 infekce jen na základě CT. Cílem studie bylo vyzkoušet použití k personalizované diagnostice u nemocných s podezřením na COVID-19.

Metodika: CT hrudníku bylo provedeno u 310 nemocných s podezřením na onemocnění COVID-19 v období března dubna 2020 v době pomalého vývoje epidemie v České republice, všichni měli provedeni následně PCT test k potvrzení virové infekce SARS-CoV-2. Porovnáním s PCR testem a do 1 týdne dostupnými dalšími

viral presence. When all RT-PCR tests had been completed and after one week of follow-up, the assessment of the sensitivity, specificity, positive and negative predictive value, and accuracy were calculated, a role of the discrimination using leukocytosis in suspected chest CT findings was evaluated respectively. One-week-follow-up was performed to assess the re-admission of the patient, and/or the COVID-19 transmission within patients or staff.

Results: The overall sensitivity of 93.75%, specificity of 94.60%, positive predictive value of 66.67%, negative predictive value of 99.25%, and accuracy 94.52 were reached; adding leukocytosis in suspected cases, specificity of 99.64%, positive predictive value of 96.77%, negative predictive value of 99.28%, and accuracy 99.03% were improved respectively. Only one re-admission with COVID-19 in formerly CT-negative was recorded. There were no noted SARS-CoV-2 transmission neither patient-to-patient, nor patient-to-staff.

Conclusion: The high negative predictive value of chest CT significantly contributed to the early identification of a large group patients with low risk for COVID-19, thus allowing them to be safely admitted outside the reserved COVID-19 units, the additional strength lies in the ability to identify an alternative non-COVID-19 diagnosis to explain the patients' clinical symptoms. The CT based approach is enabling personalized, precise and predictive approach to COVID-19 pneumonia detection.

Key words: chest CT, SARS-CoV-2 infection, COVID-19 pneumonia.

mikrobiologickými testy byla hodnocena senzitivita, specificita, pozitivní a negativní prediktivní hodnota, dále byla sledována role leukocytózy při posouzení nálezu, který byl z CT hodnocen jako podezřelý z COVID-19. Současně týdenní interval sledování byl využit také ke sledování, zda nemocný nebyl znovu přijat do nemocnice nebo zda nedošlo k infekci personálu.

Výsledky: Bylo dosaženo senzitivity 93,75 %, specificity 94,60 %, pozitivní prediktivní hodnoty 66,67 %, negativní prediktivní hodnoty 99,25 %, přesnosti 94,52 %. Přidáním leukocytózy k hodnocení podezřelých CT nálezů se specificita zvýšila na 99,64 %, pozitivní prediktivní hodnota 96,77 %, negativní prediktivní hodnota 99,28 %, přesnost 99.03 %. V celém sledovaném období byl zaznamenán pouze jediný případ opakované hospitalizace s následně potvrzeným onemocněním COVID-19 po předchozím negativním nálezu. Nebyl zaznamenán přenos infekce SARS-CoV-2 mezi pacienty nebo mezi pacientem a personálem.

Závěr: Vysoká negativní prediktivní hodnota CT hrudník jednoznačně přispěla k časné identifikaci velké skupiny nemocných s nízkým rizikem, že trpí COVID-19 pneumonií, a to dovolilo je umístit mimo pro COVID-19 rezervovaná oddělení, přídatnou hodnotou bylo také možnost identifikovat onemocnění jiná než COVID-19, a vysvětlit tak jejich symptomy. CT hrudníku tak přispělo k personalizované a prediktivní diagnostice COVID-19 pneumonie.

Klíčová slova: CT hrudníku, SARS-CoV-2 infekce, COVID-19 pneumonie.

INTRODUCTION

The spread of the new coronavirus SARS-CoV-2 has affected almost every country during the first three months of 2020. During this initial period, the epidemic developed explosively in some regions and this has recently led to the rapid overloading of health systems in places as far afield as Wuhan, Lombardy, or New York. Although CT is not recommended as, a method to confirm SARS-CoV-2 infection and the gold-standard procedure for making a diagnosis of COVID-19 is confirmation of the viral ribonucleic acid by using RT-PCR (1–3).Those procedures leading to confirmation of the diagnosis can last from several hours to days; turnaround times for COVID-19 test results range from 6 to over 48 hours with most sites waiting at least 12 hours for results. The results also closely depend on temporal-variable presentation of viral RNA within the nasopharyngeal specimen, adequacy of their taking and handling. The infection of COVID-19 could have a wide range of manifestations, with the very variable scale of severity. The personalized approach to the disease therapy needs to be used, especially in prediction of the needs of oxygenotherapy or intensive care including artificial ventilation. With the most serious clinical manifestation of SARS-CoV-2 infection being COVID-19 pneumonia, computed tomography (CT) of the chest has been reported as the most valuable imaging modality for such as manifestation of the COVID-19 disease (4–6). The appearance of COVID-19 pneumonia at CT has been described by Chinese authors, including changes related to the evolution of the disease from infection to symptom onset and then severity of the disease (7, 8). First-line CT use has been reported (9, 10), but the opinions of experts from several affected regions as to whether or not to use chest CT as the first line diagnostic test are controversial (11, 12). Although the possibility of detecting COVID-19 pneumonia

advocates the use of CT, frequent arguments against it have to be mentioned: CT suite overload, the problem of the possible further spread of the infection to medical staff and/or other patients, and the problem of insufficient SARS-CoV-2 detectability based solely on CT (10, 11). During this active COVID-19 epidemic, the problems of CT use can be assumed to be the following – logistic, sanitation including barrier protection, and diagnostic accuracy. But on the other hand, the ability of CT to differentiate other causes of the patient's state like other lung inflammation, pulmonary embolism, or malignant disease could be advantageous. The use of CT could offer the personalized approach to the precise disease differential diagnosis and could predict, whether the sever state is caused by COVID-19 with the high probability or with the other disease like bacterial pneumonia, pulmonary embolism etc.

The emergence of SARS-CoV-2 infection requires substantial in-hospital infrastructural modification to contain and isolate the number of COVID-19 suspected patients during high epidemic, during the liberalization of the anti-epidemic rules, the patients could be dissolved in other individuals. Thus, urgent decision-making and triage is of utmost importance in high epidemic, in particular for hospitals with limited number of isolated beds. With this reasoning, we aimed to examine the usefulness of CT for rapid initial triage of COVID-suspected patients and to evaluate how safely this diagnostic technique may reduce the need for strict isolation and use of restricted protection devices. The aim of this study is to indicate a role for CT in the diagnostics of COVID-19 within a region of lower population undergoing a slower evolution of the epidemic as well as to evaluate the sensitivity, specificity, predictive values and accuracy of chest CT in such a situation. The study did not focus on the severity of the disease or disease evolution prediction. Neither did it address the relation of the CT findings to the delay in onset of respiratory distress symptoms.

The aim of this study was to evaluate our experience with the personalized diagnostics of patients with clinical symptoms admitting the diagnosis COVID-19 pneumonia. Based on the above provided evidence we formulated four following clinical questions.

CLINICAL QUESTIONS

1. What is the incidence of the COVID-19 pneumonia among patients investigated using computed tomography due to severe respiratory symptoms?
2. Could the treatment be personalized according to the computed tomography finding?
3. Is the imaging technique performed suitable for stratification of the risky finding according to the severity of the disease and sufficient for proper management?
4. What are the main benefits of chest computed tomography in the prediction of severe disease's development?

Answers to these questions should serve as the main points for final assessment of clinical importance of such approach and also for assessment of benefit for patients.

METHODS

Description of the local COVID-19 epidemic

The first SARS-CoV-2 positive patients were confirmed in our country on March 1st 2020. The logistics of COVID-19 diagnostics at University Hospital were established one week later. A state of emergency was declared by the Government on March 12th 2020. After the presentation, to all radiologists of the department, of known published information about chest CT for COVID-19, we started to practice CT in this indication from the same date.

University Hospital serves as the tertiary hospital in a region with a population of 584 000 inhabitants including a metropolis of 250 000 people. The region has six additional districts mainly made up of rural settlements. During the period of investigation from March 12th to April 12th, the number of SARS-CoV-2 positive patients increased to 452 (i.e. 77.39 per 100 000 inhabitants). In one rural district of low-population, the number of positive cases has reached 254 (i.e. 409.67 per 100 000 inhabitants). The reproducibility of the infection has changed from 5.0 during the early weeks to 1.1 at the fourth week. Mortality reached 1.03 per 100 000 inhabitants.

University Hospital has centralized all symptomatic patients with COVID-19 from the whole area. With five multi-detector CTs available, both admission facilities are equipped with their own multi-detector CT serving almost exclusively for the imaging of COVID-19 suspected cases in order to prevent the mixing of the COVID-19 suspected patients with others.

The imaging, imaging evaluation and imaging based decisions

Between March 12th and April 12th, 310 patients underwent CT imaging of the chest due to suspected COVID-19 pneumonia. All patients with any respiratory symptoms or undifferentiated fever were referred to chest CT. After a basic clinical examination and blood sampling, CT was performed. The indication criteria were body temperature of more than 37.5 °C, a dry or irritating cough, myalgia, and shortness of breath, non-coronary chest pain or any other of the known clinical symptoms described for COVID-19 pneumonia.

CT was made under specific barrier regimen to minimize the risk of patient-to-staff transmission. One technician prepared the patient and set the equipment while the second technician performed the examination alone separated in an operating room. All CT examinations were performed under the following conditions: the technician inside the examination room was dressed with long-sleeve surgical coat, equipped with cap, respirator of class FFP-2, goggles, a plastic shield and double gloves. Further precautions were taken as follows - the patient was equipped with a mouth cover and single-use disposable doubled lining of the CT examination bed was used. After the scan was completed, full sanitation of the CT equipment and the entire surrounding environment was performed with the virucidal solution and, finally, the windows were opened wide. The facility was able to perform one examination every 30 minutes. All administration involved was done electronically so no paper documents were created. The informed consent was made orally in order to prevent any contamination in this exceptional emergent situation.

1a

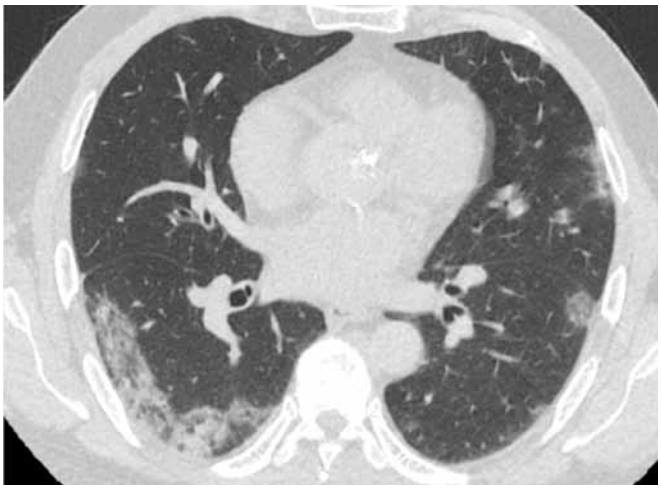

1b

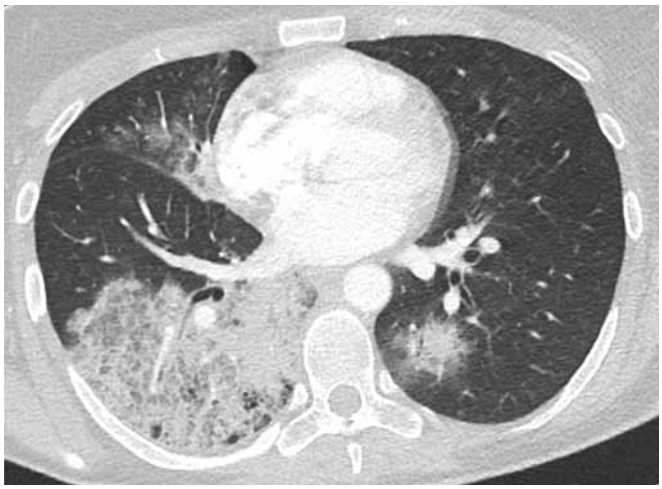

1c

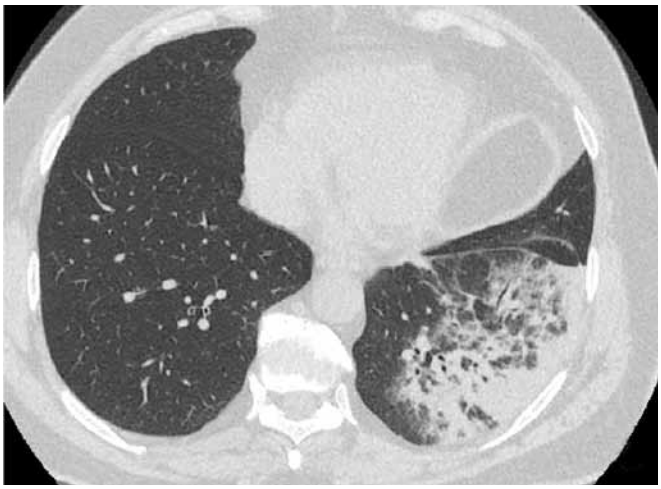

1d

1 **COVID-19 pneumonia and alternative diagnoses in symptomatic patients: (a)** COVID-19 pneumonia with typical bilateral involvement; **(b)** bacterial lobar pneumonia caused with *Streptococcus pneumoniae*, the involvement of both lungs; **(c)** pneumonia caused by *Chlamydia pneumoniae*, the unilateral unilobar involvement; **(d)** lung infarction bilateral involvement (right lung involvement at the picture), repeated SARS-CoV-PCR tests were negative

COVID-19 pneumonie a alternativní diagnózy u symptomatických pacientů: (a) COvid-19 pneumonie s typickým oboustranným postižením; **(b)** bakteriální lobární pneumonie způsobená *Streptococcus pneumoniae* s postižením obou plic; **(c)** pneumonie způsobená *Chlamydia pneumoniae*, jednostranné postižení; **(d)** plicní infarkty bilaterálně u nemocné (zobrazeno jen postižení vpravo), kde byla opakovaně negativita SARS-CoV-2 PCR testu

A total of 310 examinations were performed; 241 of these using the 320-detector-row system Aquillion One (Canon Medical Systems, Tokyo, Japan), and 69 using the system Somatom Drive (Siemens Healthineers, Forchheim, Germany). The regular chest CT exposition settings were used to reach the dose in the range of 1.0 to 2.5 mSv; low-dose imaging techniques were not used. When there was sudden chest pain and the clinical differential hypothesis was pulmonary embolism, the imaging was performed with the application of 60 milliliters of iodinated contrast material with a concentration of 350 mg of iodine per milliliter. The imaging evaluation was performed by the radiologist on duty using submillimeter isotropic images reconstructed with a high-resolution algorithm appropriate to lung parenchyma assessment, the second opinion was made by the senior consultant radiologist in all imaging.

The multimodality platform Syngo. Via (Siemens Healthineers, Forchheim, Germany) were used to assess the parenchymal changes in a three dimensional environment using. The previously described changes related to COVID-19 were investigated: ground-glass opacities, mixed ground-glass opacities, thickening of intra-lobular septa, negative bronchogram, reverse halo sign, and dilatation of the vascular structures. Predominant peripheral, bilateral and caudal distributions were suspected to be COVID-19 pneumonia. The criteria described in previously published reports for establishing a diagnosis of COVID-19 pneumonia were used. The written findings contained the final conclusion using one of the four following statements – 1. no pathological finding, 2. finding highly suspected of viral pneumonia related to COVID-19, 3. other pathological finding with specification (for example non-COVID-19

lung inflammation such as lobar pneumonia, bronchopneumonia, lung tumor, pulmonary embolism, pleural effusion, left heart failure, etc.).

According to the clinical examination, red and white cell count and basic biochemistry, and the CT finding, a patient triage was made regarding the appropriate bed units. Patients highly suspected of having COVID-19 pneumonia were isolated at the Department of Infectious Diseases or a specialized COVID-19 ICU. Those with another kind of lung inflammation (other than COVID-19 pneumonia) or other pathologies (left heart failure, pulmonary embolism, or tumor) were hospitalized at the intermediate bed unit with isolated rooms, and they stayed there until confirmation of the negative RT-PCR finding. All patients with no serious symptoms and with a negative CT finding were released from hospitalization. All admitted patients underwent sampling for RT-PCR to confirm the presence of viral SARS-CoV-2 ribonucleic acid; the serology, and/or cultivation were used to identify the cause of pneumonia in SARS-CoV-2 negatives. The response to antibiotic therapy was investigated, when no microbial cause was determined. A one week follow-up of all patients was performed to rule out a late onset of symptoms of COVID-19 pneumonia requiring re-admission to hospital.

When consecutive two SARS-CoV-2 RT-PCR tests had been completed and after two weeks of follow-up related to the common incubation time of COVID-19, the assessment of the sensitivity, specificity, positive and negative predictive value, and accuracy according to the detection of COVID-19 pneumonia were calculated respectively. The true positives were patients with confirmed SARS-CoV-2 in any of at least two samples, or with repeated negativity but highly suspected due to CT findings with the presence of IgG specific antibodies. The false positives were all patients with findings that made them suspected but with a different cause of pulmonary changes. The true negatives were patients with no pulmonary findings and with two subsequent negative RT-PCR taken 24 hours apart. The false negatives were patients with no findings of suspected COVID-19 pneumonia and with a positive RT-PCR finding. In those patients, when findings suggested suspected COVID-19, the simple additional test – leukocytosis of more than 10 000 per milliliter was added to the CT findings to distinguish the COVID-19 pneumonia from any other lung inflammation. Splitting the false positive patients into groups with or without leukocytosis, a second calculation was made. Those with leukocytosis were then included in the true negative group.

The study was as a retrospective analysis of prospectively collected data, given a descriptive design collecting only aggregate data without patient identifiers, an approval was not required from the hospital's Institutional Review Board.

RESULTS

The description of a cohort with results are summarized in Tables 1a–c. From 310 subjects, COVID-19 related disease was confirmed in 32 patients. The radiologist on duty identified COVID-19 pneumonia correctly; in two patients with proven COVID-19, no signs related to pneumonia were found. In an additional 15 patients, the chest CT was described as showing suspected COVID-19 pneumonia, but the RT-PCR for SARS-CoV-2 was negative at the two following RT-PCR tests. When the leukocytosis was used as a discriminating criterion in the group with CT findings suggesting suspected COVID-19, no patient with consequently proven COVID-19 had leukocytosis of more than 10 000 per milliliter. In the group of COVID-19 negative patients, 14 of 15 patients presented elevated white cell counts. The lung findings mimicking COVID-19 pneumonia are listed in Table 2. The incidence of the COVID-19 pneumonia among patients investigated using computed tomography due to severe respiratory symptoms remains low, the alternative diagnoses dominate.

An important discrepancy between CT findings of suspected COVID-19 and negative RT-PCR was found in three patients: two had SARS-CoV-2 negative at the first RT-PCR while the second was positive; and one additional patient had three RT-PCR negative results but the further test of IgG specific antibodies confirmed the infection of SARS-CoV-2.

Table 1a. **Cohort description**

Tab. 1a. **Popis souboru nemocných**

	All patients		COVID-19		Non-COVID-19 inflammation		Other pathology		No pathology	
Age	**No.**	**%**	**No.**	**%**	**No.**	**%**	**No.**	**%**	**No.**	**%**
0–19	3	0.97	1	3.13	1	0.94	0	0	1	0.76
20–29	23	7.42	0	0	6	5.66	3	7.32	14	10.69
30–39	16	5.16	0	0	1	0.94	2	4.88	13	9.92
40–49	33	10.65	4	12.50	12	11.32	3	7.32	14	10.69
50–59	44	14.19	3	9.38	18	16.98	4	9.76	19	14.50
60–69	63	20.32	13	40.63	19	17.92	9	21.95	22	16.79
70–79	76	24.52	5	15.63	29	27.36	14	34.15	28	21.37
80+	52	14.77	6	17.75	20	18.87	6	14.63	20	15.27
all	310	100.00	32	100.00	106	100.00	41	100.00	131	100.00
males	165	53.23	18	56.25	59	55.66	24	58.54	64	48.86
females	145	46.27	14	43.75	47	44.34	17	41.46	67	51.14
mean age	61.73		65.66		64.04		63.88		58.47	
range	15–91		17–86		15–91		22–89		15–91	

Table 1b. **Findings of chest CT and the following care based on CT finding**

Tab. 1b. **Nález CT hrudníku a následná léčba**

No.	%	
131	42.26	no relevant pulmonary pathology, home care
91	29.35	non-COVID-19 pulmonary inflammation, hospitalized on non-COVID-19 units
41	13.23	other important pathology, care depending on the cause
14	4.52	pulmonary inflammation, CT finding COVID-19 suspected, leukocytosis more than 10 000/ml, RT-PCR negative, solely hospitalized on quarantine bed unit untill negative RT-PCR
1	0.32	pulmonary inflammation, CT finding COVID-19 suspected, no leukocytosis, RT-PCR negative, solely hospitalized on quarantine bed unit untill negative RT-PCR
12	3.87	COVID-19 RT-PCR positive, severe lung involvement on CT, oxygen hyposaturation, need of intensive care on COVID-19 unit
18	5.81	COVID-19 RT-PCR positive, mild pulmonary CT findings, standard care on COVID-19 bed unit
2	0.65	COVID-19 RT-PCR positive, minimal CT findings, standard care on COVID-19 bed unit
310	100.00	all

Table 1c. **Diagnostic performance of chest CT in differential diagnostics of COVID-19 pneumonia**

Tab. 1c. **Hodnocení diagnostického přínosu CT hrudníku v diferenciální diagnostice**

*Including leukocytosis		*
sensitivity	93.75	93.75
specificity	94.60	99.64
positive predictive value	66.67	96.77
negative predictive value	99.25	99.28
accuracy	94.52	99.03

In relation to those findings, the treatment could be personalized according to the computed tomography finding since the admission of the patient to the hospital, even more non-COVID-19 lung inflammation was described by the radiologist in 91 patients at the time of imaging evaluation, some further successfully treated with antibiotics. None of those patients had a positive RT-PCR for SARS-CoV-2 and none of them returned with COVID-19. Table 3 summarizes the causes of non-COVID-19 lung inflammation, truly identified by CT as COVID-19 negative. Clinical symptoms similar to COVID-19 were seen in 41 patients with other pathologies like lung edema in left heart failure, lung infarction in pulmonary embolism, and patients with lung carcinoma, metastases of extra-thoracic tumors, lymphoma or accidentally found tumors of extra-thoracic organs seen on the chest CT (Table 4). No pulmonary pathology was identified by the chest CT in 131 patients and no one of those patients came back with COVID-19 pneumonia; only one patient has since returned, in one older male, two tests RT-PCR were negative and although the additional RT-PCR became positive after one week, the chest CT remained without signs of COVID-19 pneumonia.

Table 2. **Pulmonary inflammation, CT suspected from COVID-19, but SARS-CoV-2 RT-PCR negatives and their treatment**

Tab. 2. **Plicní infekce u CT podezřelých nálezů z COVID-19, ale SARS-CoV-2 RT-PCR negativních a jejich léčba**

Pulmonary inflammation, CT finding suspected from COVID-19 *SARS--CoV-2 RT-PCR negative*	**No.**
community acquired pneumonia, no confirmed cause, responded to antibiotics (incl. 1 patient with leukopenia)	2
Escherichia coli	6
Chlamydia pneumoniae	4
Pseudomonas aeruginosa	1
Chlamydia trachomatis	1
Influenza A virus	1
total	**15**

According COVID-19 contagious safety, neither SARS-CoV-2 transmission related to patient-staff nor patient-patient has noted during the follow-up. During the controlled period, also no transmission patient-to-staff has been noted within the whole hospital.

DISCUSSION

What is the incidence of the COVID-19 pneumonia among patients investigated using computed tomography due to severe respiratory symptoms?

Many current studies have indicated that the feasibility of CT use for early diagnosis of SARS-CoV-2 infection needs further investigation (13, 14). Establishing chest CT as one of the first line tests could be problematic during this explosive epidemic, especially due to logistical reasons (10, 15). When the number of patients suffering from symptoms of COVID-19 pneumonia is relatively limited and the hospital is equipped with multiple CTs, CT workplace overload or the mixing of COVID-19 suspected and non-suspected patients is less likely. The reasonable use of chest CT could be especially when the patients with COVID-19 are dissolved within the population and those with severe respiratory symptoms are recommended to CT. Because of some government-initiated restrictions, especially general quarantine, which have been employed in some countries to slow down the spread of the epidemic, linear growth of the number of COVID-19 positive patients has occurred, following the descending number of cases, the COVID-19 pneumonia remains the one of the wider ranged possible causes of respiratory symptoms. The experiences from the first wave has given hospitals the chance to organize the first-line diagnostics of patients with symptoms of suspected COVID-19 pneumonia during slow epidemic phase or during the returning second wave.

Is the imaging technique performed suitable for stratification of the risky finding according to the severity of the disease and sufficient for proper management?

Even during a slowly growing COVID-19 epidemic, our report reflects our own experience with the use of chest CT in

patient triage to select those needing isolation, expected to require intensive care, and last but not least to prevent the mixing of SARS-CoV-2 positive and negative patients within rooms or bed units. The triage of the patients admitted to hospital is crucial to limit the spread of disease both within the hospital and the vulnerable patient population. Most patients arrive with fever and/or respiratory symptoms which are very common in many other diseases (16, 17). The Chinese studies frequently use clinical classification (8, 18–20), dividing the disease appearance into:

1. mild type with mild clinical symptoms, without findings of pneumonia
2. common type with fever, respiratory tract and other symptoms with pneumonia seen in imaging
3. severe type with respiratory distress, a respiratory rate 30 times/min and more in a resting state and oxygen saturation of 93% or less in air, and PaO_2/300 mmHg or less and finally
4. critical type with respiratory failure requiring mechanical ventilation, shock and other organ failure requiring ICU monitoring and treatment. The rate of these above mentioned types vary according to: the number of tested people, ethnicity, and according to the epidemic situation (7, 21, 22)

Table 3. **Causes of pulmonary inflammation in non-COVID-19 patients, CT was not suspected form COVID-19**

Tab. 3. **Příčiny zánětu plic u non-COVID-19 pacientů, kde nález CT nebyl podezřelý z COVID-19**

Pulmonary inflammation, cause confirmed by cultivation, serology or PCR	No.	%
communitiy acquired pneumonia, no confirmed cause, responded to antibiotics	45	42.45
Chlamydia pneumoniae	20	18.87
Influenza A virus	10	9.43
Escherichia coli	8	7.55
Staphylococus aureus, methiciline sensitive	5	4.72
Streptococcus pneumoniae	4	3.77
Enterobacter cloacae	2	1.89
Mycolasma pneumoniae	2	1.89
respiratory syncytial virus	2	1.89
Aspergillus sp.	2	1.89
Epstein-Baar virus	1	0.94
Adenovirus	1	0.94
Chlamydia trachomatis	1	0.94
Mycobacterium tuberculosis	1	0.94
Streptococcus beta-hemolytic	1	0.94
Pseudomonas aeruginosa	1	0.94
total	**106**	**100.00**

Table 4. **Other important pathologies in non-COVID-19 patients**

Tab. 4. **Ostatní důležité patologické nálezy u non-COVID-19 pacientů**

Other important pathology	No.	%
left heart failure, interstitial or alveolar edema	9	21.95
pulmonary embolism	7	17.07
lung carcinoma, known, complication	3	7.32
lung carcinoma, newly detected	3	7.32
lung metastases	3	7.32
pleuritis	3	7.32
interstitial lung disease	3	7.32
lymphoma	2	4.89
colitis	2	4.89
lung contusion	1	2.44
sarcoidosis	1	2.44
pneumothorax	1	2.44
acute pancreatitis	1	2.44
liver tumor – hepatocellular carcinoma	1	2.44
pyelonefritis	1	2.44
total	**41**	**100.00**

Could the treatment be personalized according to the computed tomography finding?

Because the symptoms that lead patients to go to hospital are typically symptoms of a common to severe type, during the slow-down of the epidemic the patients with COVID-19 could be more likely to be mixed with patients suffering from the same symptoms, but suffering from different diseases. Chest CT could improve the personalized approach to the patient, making the individualized treatment possible, according to the different causes or different level of care, from standard bed to intensive care. The important aspect is also, that SARS-CoV-2 is highly contagious, and when the mortality is increasing in the vulnerable population, it seems to be more acutely crucial at the time to separate those with highly suspected COVID-19 from those less suspected of having it. Such a splitting up of the patients helps to prevent the spread of SARS-COV-2 within the bed units in hospital and reduces the risk of infection amongst medical staff.

What are the main benefits of chest computed tomography in the prediction of severe disease's development?

Even if the epidemic exceeds the current number of COVID-19 cases, those other causes of the symptoms similar to COVID-19 should not be missed (17, 23), vice-versa during slowing down the COVID-19 pneumonia has not to be missed among other lung infections. Our results are consistent with previously described CT findings of COVID-19 pneumonia whereby the sensitivity is high (3), our reached 93.75. Many studies reported that the appearance of COVID-19 pneumonia is similar to other viral pneumonia (25–27). The problem of the previously published reports was low specificity (3, 13), and

low specificity is one of the strongest arguments (along with the logistics and problems with suite disinfection) against CT as a first-line test (10, 12). Our specificity of the chest CT reaches 94.60. What reason could there be for this? The possibility of using one CT suit for the first-line COVID-19 imaging is crucial. The organization of the care at the admission unit with a clinically well-made preselection of patients is an important reason. The well-educated and well-prepared radiologist on duty had experience with other previous epidemic lung infections. From the point of view of clinical relevance of chest CT in COVID-19 examinations, the predictive values are very important. The positive predictive value (PPV) predicts the need for direct patient isolation. We only reached a value of PPV 66.67 using chest CT findings alone. When the simple information of white cell count was added, PPV increased to 96.77. On the other hand, the negative predictive value (NPV) has the most important impact on omission of isolation; our reached 99.25. Those result are very important due to the personalized treatment of patients.

Coronavirus SARS-CoV-2 is being very contagious, the transmission is possible not only thanks to droplet infection, but also due to the contamination of the surfaces. Thus transmission-safety has been discussed in relation to the use of CT in the diagnosis of COVID-19 very intensively (4, 10). No imaging-related transmission in our relatively large cohort (patient-to-patient or patient-to-staff) has confirmed the procedure's safety, and the sufficiency of the used barrier and decontamination regimen.

The study limitations were the retrospective analysis of the prospectively collected data, with relatively limited follow-up period; the relatively low incidence of the COVID-19 in the area; and/or the low density of the settlement. Those factors could involve the general application of the results.

CONCLUSION

The indicative value of the first-line chest CT in detection of COVID-19 pneumonia will increase during the further development of the epidemic in many other countries when the persistence of the SARS-CoV-2 infection in the population is not possible to predict. CT significantly contributed (with high NPV) to the early identification of a large group patients with low risk for COVID-19, thus allowing them to be safely admitted outside the reserved COVID-19 units, this is one of the most important contribution to the personalized and precision treatment of them. As a result of this personalized COVID-19 detection, this approach significantly preserved healthcare resources as well as the potential of transmitting SARS-CoV-2 infection from positive patients in bed units. Another major strength of CT-based approach of differential diagnostic of COVID-19 in slow epidemic lies in the ability to identify an alternative non-COVID-19 pneumonia and the other diagnoses to explain the patients' clinical features and to direct the patients' care as appropriate. The predictive effect of chest CT is pointed at highly accurate detection of patients with severe lung affection by COVID-19 pneumonia has to be able to identify those who have to be isolated and may require ICU care.

REFERENCES

1. **Yang W, Yan F.** Patients with RT-PCR Confirmed COVID-19 and Normal Chest CT. Radiology 2020 Mar 6: 200702. doi: 10.1148/radiol.2020200702
2. **Long C, Xu H, Shen Q, et al.** Diagnosis of the Coronavirus disease (COVID-19): rRT-PCR or CT? Eur J Radiol 2020; 126: 108961. doi: 10.1016/j.ejrad.2020.108961
3. **Ai T, Yang Z, Hou H, et al.** Correlation of Chest CT and RT-PCR Testing in Coronavirus Disease 2019 (COVID-19) in China: A Report of 1014 Cases. Radiology 2020 Feb 26; 200642. doi: 10.1148/radiol.2020200642
4. **Rubin GD, Ryerson CJ, Haramati LB, et al.** The Role of Chest Imaging in Patient Management during the COVID-19 Pandemic: A Multinational Consensus Statement from the Fleischner Society. Radiology 2020 Apr 7; 201365. doi: 10.1148/radiol.2020201365
5. **Bernheim A, Mei X, Huang M, et al.** Chest CT Findings in Coronavirus Disease-19 (COVID-19): Relationship to Duration of Infection. Radiology 2020 Feb 20; 200463. doi: 10.1148/radiol.2020200463
6. **Wang K, Kang S, Tian R, et al.** Imaging manifestations and diagnostic value of chest CT of coronavirus disease 2019 (COVID-19) in the Xiaogan area. Clin Radiol 2020; 75(5): 341–347. doi: 10.1016/j.crad.2020.03.004
7. **Zhou S, Wang Y, Zhu T, Xia L.** CT Features of Coronavirus Disease 2019 (COVID-19) Pneumonia in 62 Patients in Wuhan, China. AJR Am J Roentgenol 2020; 5: 1–8. doi: 10.2214/AJR.20.22975
8. **Li K, Fang Y, Li W, et al.** CT image visual quantitative evaluation and clinical classification of coronavirus disease (COVID-19). Eur Radiol 2020 Mar 25. doi: 10.1007/s00330-020-06817-6
9. **Huang Y, Cheng W, Zhao N, Qu H, Tian J.** CT screening for early diagnosis of SARS-CoV-2 infection. Lancet Infect Dis 2020 Mar 26. pii: S1473-3099(20)30241-3. doi: 10.1016/S1473-3099(20)30241-3
10. **Orsi MA, Oliva AG, Cellina M.** Radiology Department Preparedness for COVID-19: Facing an Unexpected Outbreak of the Disease. Radiology 2020; 295(3): E8. doi: 10.1148/radiol.2020201214 [Epub 2020 Mar 31].
11. **Wang YXJ.** A call for caution in extrapolating chest CT sensitivity for COVID-19 derived from hospital data to patients among general population. Quant Imaging Med Surg 2020; 10(3): 798–799. doi: 10.21037/qims.2020.03.04
12. **Erturk SM.** CT Is Not a Screening Tool for Coronavirus Disease (COVID-19) Pneumonia. AJR Am J Roentgenol 2020 Apr 14; W1. doi: 10.2214/AJR.20.23220
13. **Lee EYP, Ng MY, Khong PL.** COVID-19 pneumonia: what has CT taught us? Lancet Infect Dis 2020; 20(4): 384–385. doi: 10.1016/S1473-3099(20)30134-1
14. **Hope MD, Raptis CA, Shah A, Hammer MM, Henry TS; six signatories.** A role for CT in COVID-19? What data really tell us so far. Lancet 2020; 395(10231): 1189–1190. doi: 10.1016/S0140-6736(20)30728-5
15. **Mossa-Basha M, Meltzer CC, Kim DC, et al.** Radiology Department Preparedness for COVID-19: Radiology Scientific Expert Panel. Radiology 2020 Mar 16; 200988. doi: 10.1148/radiol.2020200988
16. **Himoto Y, Sakata A, Kirita M, et al.** Diagnostic performance of chest CT to differentiate COVID-19 pneumonia in non-high-epidemic area in Japan. Jpn J Radiol 2020 Mar 30. doi: 10.1007/s11604-020-00958-w

17. **Hani C, Trieu NH, Saab I, et al.** COVID-19 pneumonia: A review of typical CT findings and differential diagnosis. Diagn Interv Imaging 2020 Apr 3. pii: S2211-5684(20)30091-7. doi: 10.1016/j.diii.2020.03.014
18. **Li K, Wu J, Wu F, et al.** The Clinical and Chest CT Features Associated with Severe and Critical COVID-19 Pneumonia. Invest Radiol 2020 Feb 29. doi: 10.1097/RLI.0000000000000672
19. **Zhao W, Zhong Z, Xie X, Yu Q, Liu J.** Relation Between Chest CT Findings and Clinical Conditions of Coronavirus Disease (COVID-19) Pneumonia: A Multicenter Study. Am J Roentgenol 2020 Mar 3; 1–6. doi: 10.2214/AJR.20.22976
20. **Xiong Y, Sun D, Liu Y, et al.** Clinical and High-Resolution CT Features of the COVID-19 Infection: Comparison of the Initial and Follow-up Changes. Invest Radiol 2020 Mar 3. doi: 10.1097/RLI.0000000000000674
21. **Caruso D, Zerunian M, Polici M, et al.** Chest CT Features of COVID-19 in Rome, Italy. Radiology 2020 Apr 3; 201237. doi: 10.1148/radiol.2020201237
22. **Chua F, Armstrong-James D, Desai SR, et al.** The role of CT in case ascertainment and management of COVID-19 pneumonia in the UK: insights from high-incidence regions. Lancet Respir Med 2020 Mar 25. pii: S2213-2600(20)30132-6. doi: 10.1016/S2213-2600(20)30132-6
23. **Dai WC, Zhang HW, Yu J, et al.** CT Imaging and Differential Diagnosis of COVID-19. Can Assoc Radiol J 2020; 71(2): 195–200. doi: 10.1177/0846537120913033.
24. **Fang Y, Zhang H, Xie J, Lin M, Ying L, Pang P, Ji W.** Sensitivity of Chest CT for COVID-19: Comparison to RT-PCR. Radiology 2020 Feb 19; 200432. doi: 10.1148/radiol.2020200432 [Epub ahead of print]. PubMed PMID: 32073353.
25. **Bai HX, Hsieh B, Xiong Z, et al.** Performance of radiologists in differentiating COVID-19 from viral pneumonia on chest CT. Radiology 2020 Mar 10; 200823. doi: 10.1148/radiol.2020200823
26. **Li M, Lei P, Zeng B, et al.** Coronavirus Disease (COVID-19): Spectrum of CT Findings and Temporal Progression of the Disease. Acad Radiol 2020 Mar 20. pii: S1076-6332(20)30144-6. doi: 10.1016/j.acra.2020.03.003
27. **Cheng Z, Lu Y, Cao Q, et al.** Clinical Features and Chest CT Manifestations of Coronavirus Disease 2019 (COVID-19) in a Single-Center Study in Shanghai, China. Am J Roentgenol 2020 Mar 14; 1–6. doi: 10.2214/AJR.20.22959
28. **Wang YXJ, Liu WH, Yang M, Chen W.** The role of CT for Covid-19 patient's management remains poorly defined. Ann Transl Med 2020; 8(4): 145. doi: 10.21037/atm.2020.02.71